

Knee Trauma

Patient History

18-year-old male patient presenting with knee trauma. Standard 2D X-ray imaging was performed as the routine imaging choice. Imaging on the CARESTREAM OnSight 3D Extremity System was ordered due to inconclusive findings on the 2D radiographs.

Findings

The traditional 2D projection X-rays (see Figure 1) show no clear evidence of fracture but did show intra-articular fluid. Patient was unable to walk, which is not typically consistent with ligament/soft tissue damage and a tibial plateau fracture was suspected. Normal protocol would be for the patient to be given an MRI at 2-3 weeks post injury.

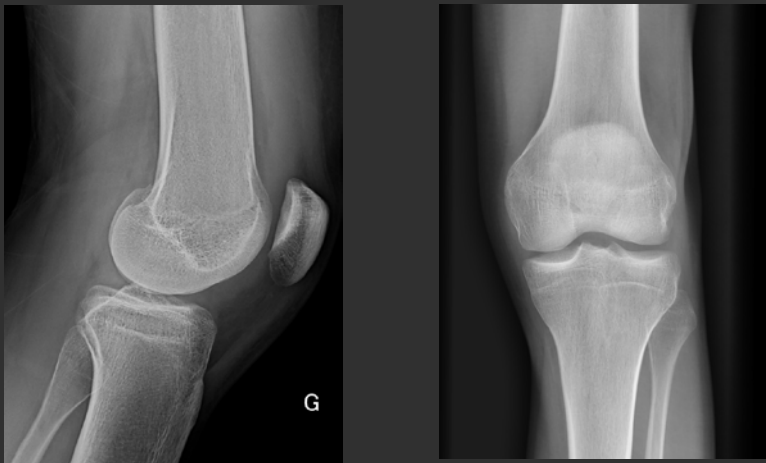

Figure 1 Standard 2D X-ray of knee trauma patient. Evidence of intra-articular fluid, but with no obvious fracture seen.

Figure 2 shows an axial and sagittal slice from the patient's CARESTREAM OnSight 3D Extremity System scan that shows a classic impaction fracture of the posterior aspect of the lateral tibial plateau missed on the 2D X-rays.

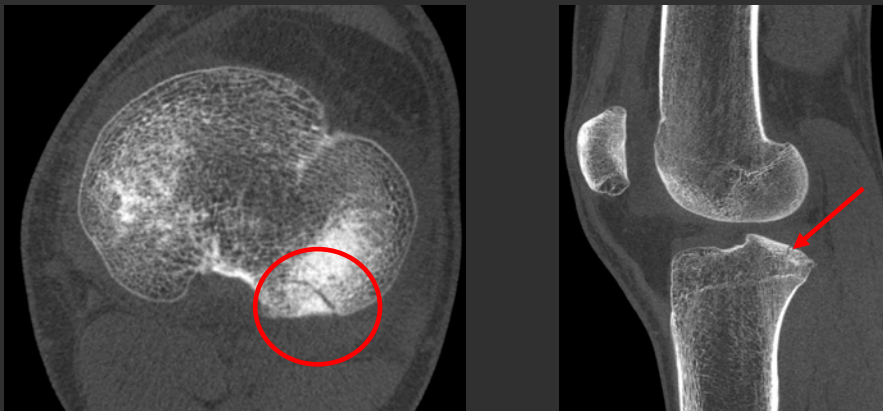


Figure 2 Axial and sagittal slices from the patient acquired with the OnSight extremity CT system identifying a clear impaction fracture of the lateral aspect of the posterior tibial plateau not seen in Figure 1.

It is important that this type of fracture is identified and addressed since it can lead to osteoarthritis if left untreated. It also helps to determine the length of time the patient should be in a cast. This example highlights the value of the inherently high image quality and 3D nature of the data provided by the OnSight extremity CT system.