

Technical Brief Series

# The Benefits of Using Point-of-Care Computed Tomography (POC-CT)

## Executive Summary

Advances in cone-beam computed tomography (CBCT) technology have led to a reduction in radiation dose as well as scanner size and cost when compared to conventional multi-detector computed tomography (MDCT) technology. These advances have enabled physicians to offer POC-CT imaging in their offices.

The benefits of using POC-CT with CBCT technology for sinus and temporal bone imaging as reported in the literature are as follows:

- Immediate, accurate diagnosis
- Reduced overall healthcare costs
- High image resolution, low radiation dose
- Improved patient compliance and productivity
- Improved practice profitability and efficiency

## Background

Treatment protocols for chronic rhinosinusitis (CRS) typically recommend initial empiric medical therapy with antibiotics and corticosteroids depending on clinical symptoms. Definitive diagnostic CT scanning is reserved for nonresponders.<sup>1,2</sup>

Due to the availability of lower radiation dose technology, rising office visit and medication costs, a higher incidence of antibiotic resistance, and recent changes to CT exam reimbursements, several recently published studies have explored whether standard treatment protocols should be potentially modified.<sup>3,4,5</sup>

## Benefits of Point-of-Care CT Imaging

### Immediate, Accurate Diagnosis and Treatment

Recent reports indicate that making an upfront POC-CT exam available to patients with sinonasal complaints can change patterns of medical decision-making.<sup>3</sup> The use of POC-CT at the initial visit promoted more precise diagnoses in patients with positive CT studies, as well as a more timely application of aggressive medical therapy. Unnecessary antibiotic use and incorrect diagnostic labeling were avoided in patients with negative POC-CT findings.<sup>4</sup>

It has been reported, when measured against the gold standard CT scan, 20% to 50% of patients who display symptoms of CRS actually have the disease.<sup>5,6,7</sup> In other words, 50% to 80% of patients are being unnecessarily exposed to long courses of antibiotics and systemic steroids.

This is a critical finding as antibiotic overuse for upper respiratory complaints is a major contributor in the appearance of resistant organisms.<sup>8</sup> The established morbidity, mortality, and economic consequences associated with antibiotic resistance provides support for consideration of upfront POC-CT exams for CRS patients.

### Reduction in Chronic Rhinosinusitis Healthcare Costs

Today, symptoms of chronic rhinosinusitis (CRS) are routinely treated with empiric medical therapy before objective evidence of inflammatory disease has been demonstrated. Recent reports reveal that performing an upfront POC-CT exam when a patient first displays signs of CRS results in a substantial reduction in unnecessary antibiotic and systemic steroid costs. An upfront POC-CT can decrease the number of required office visits and lead to an estimated 25% reduction in diagnostic and treatment costs per patient.<sup>4</sup> A sensitivity analysis demonstrated a worst/best case cost reduction of 13% and 39%, respectively.

On average, patients treated with empiric medical therapy spent more on antibiotics and other medications, but less on CT exams, than the upfront POC-CT group. Return office visit costs were also lower in the upfront POC-CT group.<sup>3</sup> One benefit of fewer return office visits is the ability to accommodate more new patients in a practice.

A gross healthcare cost estimate suggests that adopting an upfront POC-CT protocol for CRS patients could save US healthcare payors as much as \$1.2 billion in healthcare costs each year.<sup>5</sup>

## White Paper | Point-of-Care CT for Sinus and Temporal Bone

### High Spatial Resolution

Cone-beam CT systems deliver isotropic, sub-millimeter spatial resolution. Due to this high resolution, POC-CTs can provide good visualization of sinus structures, sub-millimeter structures at air-bone interfaces, and middle ear and inner components and interfaces such as the tympanic membrane, ossicles, semicircular canals, mastoid air cells and cochlea.<sup>9</sup>

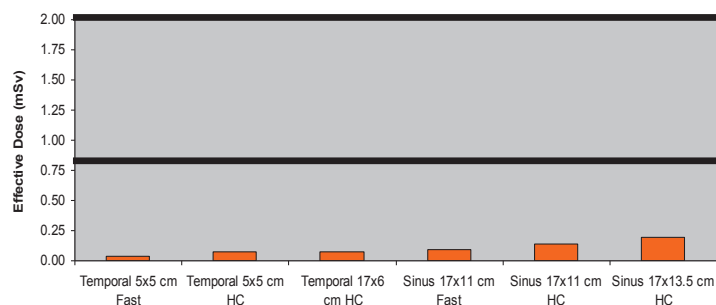
Isotropic spatial resolution has been identified as a strength of CBCT technology.<sup>9</sup> POC-CTs utilizing CBCT technology have isotropic voxels (volumetric pixels). Isotropic spatial results in highly accurate measurements that are useful for surgical planning and prosthesis design.

Cone-beam CT technology is also useful for applications requiring reduced metal artifacts, such as cochlear implant imaging, and those requiring visualization of the ossicular chain, bony labyrinth of the inner ear, internal cochlear anatomy, and the facial nerve.<sup>10</sup>

### Low Radiation Dose

A substantial reduction in radiation dose can be achieved when utilizing CBCT technology in place of conventional MDCT systems. For example, a recent technical evaluation a POC-CT (CS 9300) found that effective dose ranged from 0.09 mSv to 0.19 mSv for adult sinus protocols and 0.04 mSv to 0.08 mSv for adult temporal bone protocols (Table 1).<sup>9</sup> The corresponding absolute dose range was ~2.9 mGy to 5.7 mGy.

**Table 1** Effective Dose (mSv) of a Cone-Beam CT System<sup>9</sup> and Conventional Multi-Detector CT (MDCT) Systems<sup>11,12,13,14</sup>



The orange bars show the effective dose for various sinus and temporal bone protocols with Carestream's CS 9300 POC-CT system. The black lines show the minimum and maximum range of effective dose levels reported for conventional MDCT sinus and temporal bone exams using standard protocols

### Improved Patient Compliance and Productivity

Tan et al found that patient compliance was 100% when upfront POC-CT scans were provided to confirm evidence of inflammatory disease associated with CRS.<sup>3</sup> Only 50% of

patients returned for a post-treatment office visit when an upfront POC-CT was not performed during the initial visit, despite emphasizing the need for post-therapy evaluation to the patient.<sup>3</sup>

### Improved Practice Profitability and Efficiency

With POC-CT systems more affordable than ever, practices with both low and high CT scan volumes can experience an attractive return on investment when they offer POC-CT services.

### References

1. Benninger MS, Ferguson BJ, Hadley JA, et al. Adult chronic rhinosinusitis: definitions, diagnosis, epidemiology, and pathophysiology. *Otolaryngol Head Neck Surg* 2003;129:S1-S32.
2. Thomas M, Yawn BP, Price D, Lund V, Mullol J, Fokkens W. EPOS primary care guidelines: European position paper on the primary care diagnosis and management of rhinosinusitis and nasal polyps 2007 – a summary. *Prim Care Respir J* 2008;17: 79-89.
3. Conley D, Pearlman A, Xhou K, Chandra R, Kern R. The role of point-of-care CT in the management of chronic rhinosinusitis: A case-control study. *Ear, Nose & Throat Journal* 2011;90:8:377-391.
4. Tan BK, Chandra RK, Conley DB, Smolak Tudor R, Kern RC. A randomized trial examining the effect of pretreatment point-of-care computed tomography imaging on the management of patients with chronic rhinosinusitis symptoms. *Int Forum Allergy Rhinol* 2011;1:229-234.
5. Leung R, Kern R, Jordan N, Almassian S, Conley D, Tan B, Chandra R. Upfront computed tomography scanning is more cost-beneficial than empiric medical therapy in the initial management of chronic rhinosinusitis. *Int Forum Allergy Rhinol* 2001;1:471-480.
6. Battacharyya N. Relationship between mucosal inflammation, computed tomography, and symptomatology in chronic rhinosinusitis without polyposis. *Ann Otol Rhinol Laryngol* 2008; 117:517-522.
7. Stankiewicz JA, Chow JM. A diagnostic dilemma for chronic rhinosinusitis: definition accuracy and validity. *Am J Rhinol* 2002; 16:199-202.
8. Tamma PD, Cosgrove SE. Antimicrobial stewardship. *Infect Dis Clin North Am.* 2011;25:245-260.
9. Xu J, Reh D, Carey J, Mahesh M, Siewerdsen JH. Technical assessment of a cone beam CT scanner for otolaryngology imaging: image quality, dose and technique protocols. *Med. Phys.* Accepted for publication, July 2012.
10. Gupta R, Bartling SH, Basu SK, et al. Experimental flat-panel high-spatial-resolution volume CT of the temporal bone. *Amer J Neuroradiol* 2004;25:1417-1424.
11. Ludlow JB, Ivanovic M. Oral Surg Oral Med Oral Pathol Oral Radiol Endod 2008;106:106-114.
12. Niu Y, Wang Z, Liu Y, Liu Z, Hao V. Radiation dose to the lens using different temporal bone CT scanning protocols. *Amer J Neuroradiol* 2010;31:2:226-229.
13. Mettler FA, Wiest PW, Locken JA, Kelsey CA. CT scanning: patterns of use and dose. *J Radiol Prot* 2000;20:4:353-359.
14. Huda W, Chamberlain CC, Rosenbaum AE, Garrisi W. Radiation doses to infants and adults undergoing head CT examinations. *Med Phys* 2001;28:3:393-399.